

Fractional Photothermolysis: A Novel Aesthetic Laser Surgery Modality

BASIL M. HANTASH, MD, PhD,^{*†} AND M. BILAL MAHMOOD^{*}

The ubiquity of increased sun exposure, oral contraceptives, and phototoxic drugs has led to an increased prevalence of conditions such as dyschromia, melasma, rhytides, and other signs of photoaging over the past few decades. Through the application of selective photothermolysis, laser surgery has attempted to create therapeutic options for these medically recalcitrant conditions. To date, however, this technology has been met with limited success, due to a high incidence of posttreatment side effects, inability to treat off the face, and a safety profile tailored to Fitzpatrick skin types I to III. More recently, a novel approach coined "fractional photothermolysis" was developed in an attempt to overcome these limitations. This new laser treatment modality has allowed for effective treatment of a diverse array of dermatologic conditions on and off the face with a wider therapeutic index and improved safety profile independent of Fitzpatrick skin type. This review sheds light on the technical aspects, biologic mechanisms, and clinical effects of fractional photothermolysis that help set it apart from previous modes of laser surgery.

Basil M. Hantash, MD, PhD, has applied for patents in the use of fractional photothermolysis.

Until recently, selective photothermolysis (SP) represented the most efficacious mode of surgical laser treatment for conditions such as melasma, rhytides, scars, and photodamage.¹ By selectively absorbing short radiation pulses to photocoagulate specific chromophores such as water, hemoglobin, and melanin, SP theoretically allows for a reduction in the side effects associated with traditional surgical approaches.² In practice, however, SP applications in both ablative and nonablative modes lead to bulk heating and significant side effects, often requiring surface cooling to avoid epidermal damage.³

Ablative devices such as CO₂ lasers (10,600 nm) target water as a chromophore and are frequently used to resurface skin and effect skin tightening.⁴ Erbium: yttrium-aluminum-garnet (Er:YAG) lasers operating at 2,940 nm also function ablatively, but have been found to cause less thermal damage per pass under normal parameters.^{5,6} Although Er:YAG lasers often demonstrate more rapid healing due to

shallower absorption depths, coagulation is less efficient and more bleeding may result with increased number of passes. To overcome these limitations, some laser surgeons have combined the two platforms to improve clinical outcomes and reduce the side effect profile.⁶ Even still, ablative treatments have substantially diminished since inception due to significant patient "downtime" and adverse effects. For example, 100% of patients experience edema, burning, crusting, and erythema lasting up to 6 months after treatment.⁷ Less frequently, side effects such as pigmentary changes, infection, and scars are observed.^{5,7} The frequency of side effects of ablative lasers is summarized in Table 1.

Hemoglobin-targeting nonablative devices, such as neodymium: YAG (Nd:YAG) lasers, thermally damage dermal tissue containing blood vessels, theoretically sparing the avascular epidermis.⁷ Nd:YAG lasers, however, also target melanin as a chromophore and therefore must be used in combination with timed superficial skin cooling to reduce the

^{*}Division of Plastic Surgery; and [†]Department of Dermatology, Stanford University Medical Center, Stanford, California

TABLE 1. Comparative Summary of Selective and Fractional Photothermolysis

	<i>Selective photothermolysis</i>		
	<i>Ablative</i>	<i>Nonablative</i>	<i>Fractional photothermolysis</i>
Chromophore	Water	Hemoglobin, melanin	Water
Mode of application	Stamping approach; bulk heating	Stamping approach; bulk heating	Uniform beam; fractional heating; tissue sparing
Method of thermal damage	Epidermal vaporization and coagulation of under- lying dermis	Thermal damage mainly dermal	Columns of thermal damage in epidermis and dermis
Adverse effects (%) [*]			
Duration	Up to 6 months	Up to 1 month	Less than 1 week
Hyperpigmentation	8–68	0–39	0 [†]
Hypopigmentation	0–48	0–5.6	0
Erythema	100	100	100
Pruritis	91.3	0	37
Dryness	100	NA	28 [‡]
Acne	10–83.6	0	0–5
Milia	6–83.6	0	0
Scarring	0–8	0–2.8	0
Infection	6–8	0	0
Efficacy [§] (mean improvement, %)	63–90	10–85	75–100

*Data from References 5–8, 11, 13–14, and 20–23.

[†]Two cases of transient hyperpigmentation; data from References 8 and 23.

[‡]Data from Reference 23.

[§]Data from References 5 and 13.

likelihood of hyperpigmentation.⁵ In fact, most nonablative SP lasers rely on surface cooling to reduce thermal damage to the epidermis in hopes of mitigating adverse effects associated with treatment.⁶ In practice, however, this has led to less predictable clinical efficacy as evidenced by the broad range (10%–85%) of clinical improvement reported in the literature.⁵ The reduction in efficacy has been in part explained by a lack of epidermal contribution to the wound healing process as well as the use of epidermal cooling.

These difficulties have led to the recent development of a new laser device that relies on a novel concept coined “fractional photothermolysis” (FP).⁶ Although this is a relatively new technology whose long-term results continue to be defined, an early understanding of FP’s efficacy is beginning to emerge. This review will help shed light on FP with respect to its technical facets, biologic mechanism, and clinical effects.

Fractional Photothermolysis: A Technical Perspective

The first medical laser to utilize FP is known as the Fraxel and was developed by Reliant Technologies, Inc. (Mountain View, CA). The device employs an erbium fiber laser in conjunction with a handpiece capable of scanning across skin up to 8 cm/second while delivering a microarray pattern to a target tissue. The laser operates at a wavelength of 1,550 nm and targets water as a chromophore.⁸ The laser also utilizes an objective lens with high resolving power and an adjustable laser beam that can target specific depths in the skin by varying the pulse energy. Through this configuration, microscopic treatment zones (MTZs) 50 to 150 μm in diameter are generated in skin at densities ranging from 400 to 6,400 MTZ/cm² at varying microbeam spot sizes and pulse energy levels.^{7,9,10} The 1,550-nm erbium-doped fiber laser delivers up to 3,000 precision pulses per second with each pulse inducing a

single MTZ. Pulses of 6, 10, 12, and 20 mJ are commonly selected for treatment, usually at a microbeam spot size of $140\ \mu\text{m}$ $1/e^2$.⁹ A 60- μm spot size was also developed but appears to induce more rapid vaporization of the epidermis, making the 140- μm spot size the current standard of practice.

The 1,550-nm fiber laser's versatility and innovative handpiece allows the physician to treat in scanning mode, unlike nonfractional laser devices that generally depend on a "stamping" approach. The latter involves marching the handpiece across the skin in succession from one area to the next until the entire target has been treated. This method increases the probability of developing posttreatment areas of separation and the production of Moire artifacts upon multiple passes of the device (Figures 1A and 1B). Conversely, the fractional nonablative laser utilizes a specialized beam deflector and high-speed pattern generator that allows for deposition of MTZs in random patterns through a continuous beam (Figure 1C). This creates a more blended appearance after treatment. In addition, the pattern generator technology allows for improved reliability by ensuring interbeam fidelity. Thus, each beam maintains the same energy profile, a feat not yet proven possible through the use of microarray filters.

The laser's Intelligent Optical Tracking system (IOTS) is one of the key technical components that allowed overcoming the limitations of stationary treatment. By applying a blue dye to the skin before treatment, the IOTS monitors user hand speed and only treats areas with adequate dye contrast. In addition, the high-speed pattern generator assists the IOTS by maintaining a constant MTZ density, further avoiding the production of nonuniform treatment patterns.

Before the development of the IOTS and FP, treatment of photoaging was limited to facial areas due to the higher risk of permanent scars and/or hyperpigmentation associated with off-the-face treatments.

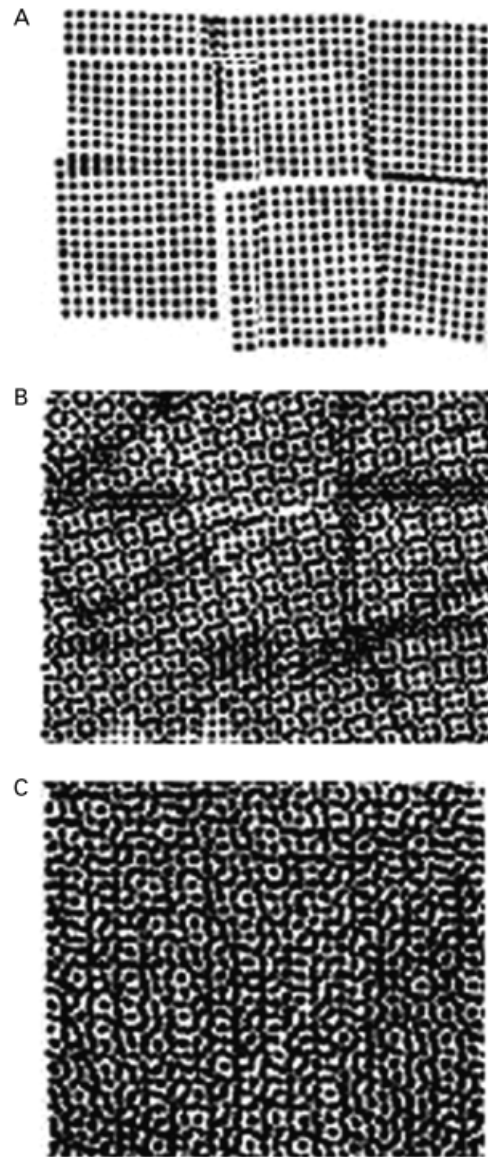


Figure 1. Comparison of stamping versus scanning mode laser treatments. (A) Human error while using a stamping approach often results in gaps between treatment areas. (B) Multiple passes were often necessary to account for such inefficiency, but in turn contributed to the stimulation of Moire artifacts. (C) In contrast, the 1,550-nm erbium-doped fiber laser in conjunction with a scanning device stimulates a randomized microscopic treatment zone pattern on the affected tissue devoid of gaps in treatment and Moire artifacts.

This increased incidence of side effects in off-the-face sites is a problem commonly observed with SP laser devices that treat skin macroscopically (spot size, $>500\ \mu\text{m}$) and can be attributed to several factors such as bulk heating, less vigorous vascular supply,

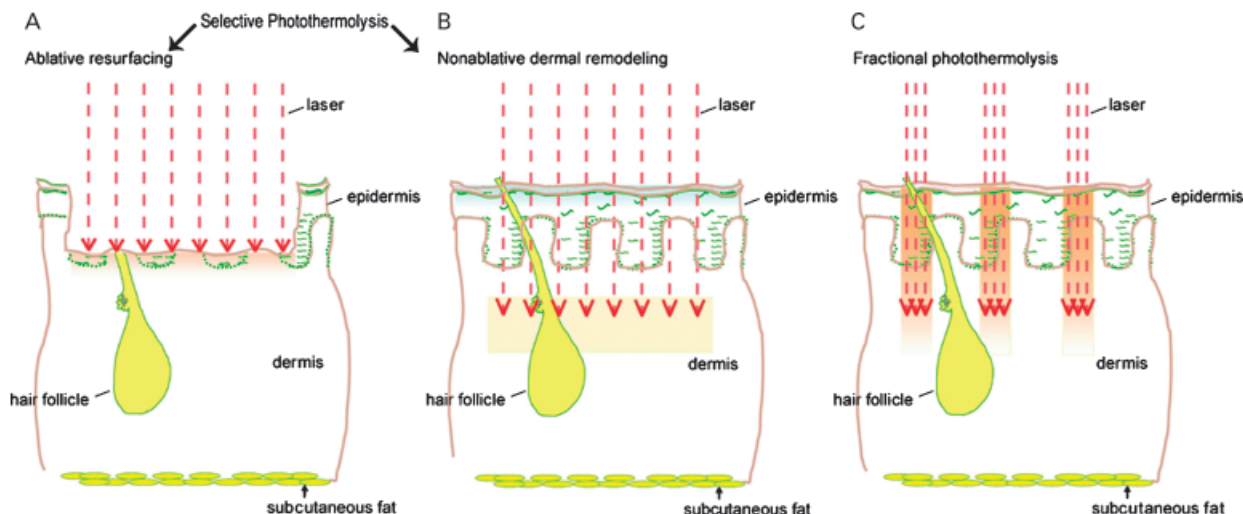


Figure 2. Comparison of tissue damage zones of selective versus fractional photothermolysis treatment modes. (A) Ablative resurfacing induces thermal damage beneath the zone of vaporization without sparing dermal tissue. Epidermal healing is slow and only occurs in a centripetal pattern at the edge of the macroscopic wound. (B) Nonablative remodeling thermally damages dermal tissue but completely spares the epidermis. Dermal wound healing is limited to a centripetal process that begins at the edges of the macroscopic damage zone. (C) Fractional photothermolysis treats only a portion of epidermal and dermal tissue. Microscopic damage zones constitute no more than 20% of the total surface area. Wound healing occurs rapidly due to significant contributions from the macroscopic spared zone. Modified with permission from Manstein et al.⁶

and reduced hair follicle density. The limitations with this macroscopic approach are even more pronounced when using nonfractional ablative devices that often completely destroy the epidermis, the primary layer contributing to rapid reepithelialization.⁶ In sharp contrast, the fractional laser device coagulates on average 20% of the target area thus minimizing unnecessary thermal damage.¹¹ This has permitted successful treatment off the face while preserving rapid healing times.⁷ It should be noted, however, that overzealous treatment ($>4 \text{ J/cm}^2$) with the fractional nonablative laser in the absence of epidermal cooling may lead to the untoward effects of bulk heating. In an attempt to further protect against this possibility, many physicians have begun using forced-air cooling in conjunction with higher energy treatments.¹² Finally, pulse stacking and consequent bulk heating may occur when treating a region with multiple passes in rapid succession (less than 15 seconds between consecutive passes). Avoidance of both these scenarios will help diminish adverse events and ensure patient safety. A summary of the three modes of treatment under current use is shown in Figure 2.

Biology of Fractional Photothermolysis

Perhaps the most interesting feature of FP is the biological mechanism that underlies its clinical efficacy. Targeting water as a chromophore rather than hemoglobin or melanin, FP has substantial adaptability in comparison to SP in promoting thermal damage to a multitude of water-rich targets such as epidermal keratinocytes, collagen, and blood vessels located at varying depths throughout skin.¹⁰ Unlike nonfractional laser devices that use a macroscopic spot size, the 1,550-nm erbium-doped fiber laser was rationally designed to create MTZs as microscopic columns of thermal damage ($<500 \mu\text{m}$) to avoid bulk heating and exploit the beneficial wound healing effects of the spared viable tissue.¹³

MTZs are microscopic zones of thermal coagulation characterized by dermal collagen denaturation, as evidenced by the loss of birefringence on polarized light microscopy.¹⁴ Immediately after treatment, the MTZs histologically appear as distinct columns of thermal damage spanning the epidermis to the upper

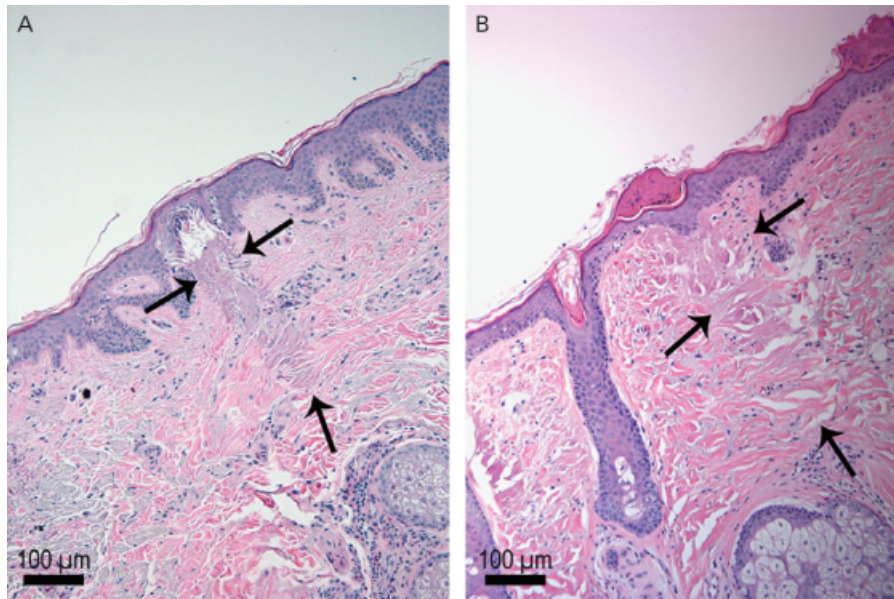


Figure 3. Histology of in vivo fractional photothermolysis treatment. (A) Human retroauricular skin was treated in vivo with a 1,550-nm erbium-doped fiber laser at a pulse energy of 8 mJ immediately before facial reconstructive surgery. Tissue was then excised and processed for hematoxylin and eosin staining. A zone of thermal coagulation 100 μm in diameter is evident (arrows). A cavity is apparent in the lower epidermis although the stratum corneum remains intact. (B) Same as in A except tissue was excised from human preauricular skin 3 days after treatment. Most of the epidermis has reepithelialized with near complete restoration of the basement membrane. A button-like eosinophilic staining coagulum can be seen in the stratum corneum. Original magnification, $\times 10$.

half of the dermis, with large zones of noncoagulated tissue between lesions (Figure 3A). These interlesional zones retain birefringence and have been shown to be viable by lactate dehydrogenase staining (personal communication). The combination of interlesional sparing and treatment of the epidermis appear to underlie FP's ability to stimulate rapid reepithelialization of damaged tissue as well (Figures 2C and 4A).⁹ Slow reepithelialization remains one of the primary problems plaguing nonfractional ablative devices and likely is due to a lack of participation of viable epidermis in the wound healing process (Figure 2A).⁵ In the case of nonablative SP devices, the opposite holds true and complete protection of the epidermis (via cooling) prohibits rapid epidermal turnover leading to reduced efficacy as a resurfacing treatment (Figures 2B and 4B). Interestingly, however, fractional treatment with the 1,550-nm erbium-doped fiber laser maintains an intact stratum corneum thereby preserving its barrier function and protecting against microbial infection (Figures 3A and 3B).⁹

In fact, the skin barrier function continues unabated in parallel with exfoliation of coagulated tissue, otherwise known as microepidermal necrotic debris (MEND). This material is button-shaped and hypercompact with each MEND ranging 50 to 200 μm in diameter (personal communication).⁶ Our recent studies have demonstrated the presence of both melanin and elastin within the MEND. It appears that FP is capable of activating a transepidermal elimination process that removes coagulated tissue of dermal and epidermal origin.⁹ This may explain reports of FP's consistent improvement of dermal melasma, a very difficult-to-treat dermatologic condition that has thus far evaded all medical therapy.¹³

As a result of the epidermal coagulation by FP, transiently amplifying epidermal stem cells located in the basal layer are activated and begin to proliferate to rapidly replace the damaged epidermal tissue.⁷ This response to thermal damage can be partially explained by the initiation of a biologic signaling

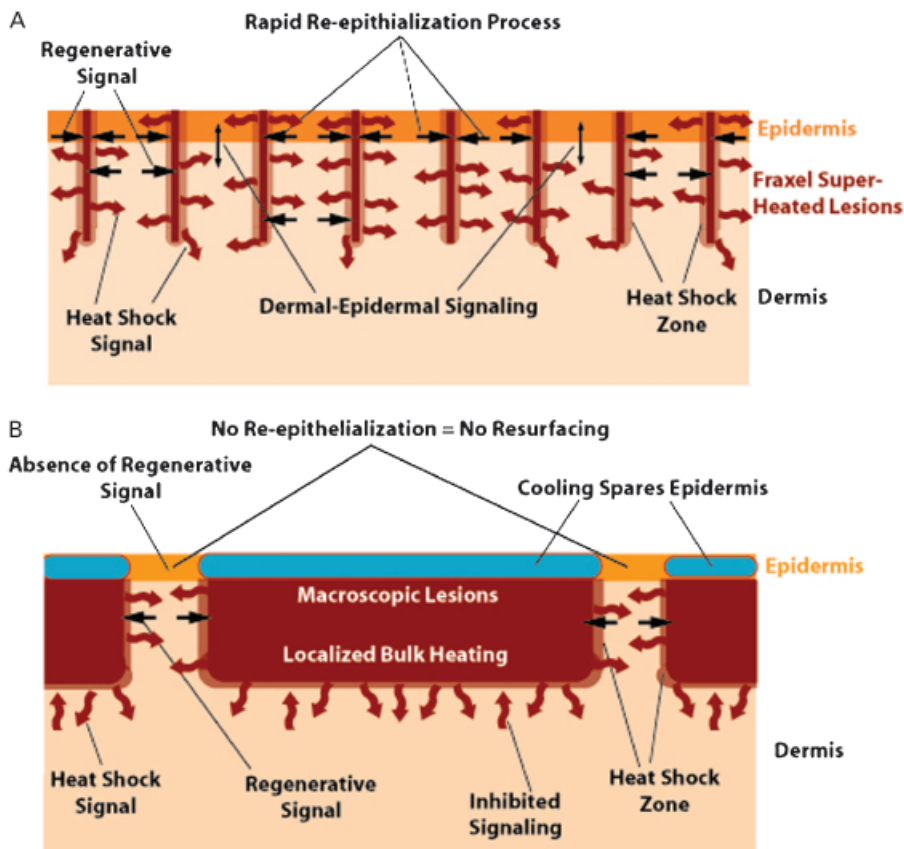


Figure 4. Model of reepithelialization process after fractional versus selective photothermolysis treatment. (A) In fractional photothermolysis, the thermal damage zone never exceeds the size of the spared zone. Within 1 day after treatment, critical response mediators are released by tissue in the heat shock zone. Zones of spared epidermis and dermis initiate a signaling cascade leading to up-regulation of basal epidermal stem cell activity and rapid reepithelialization. Dermal-epidermal signaling continues to promote dermal remodeling for several months after treatment. (B) In selective photothermolysis, conventional nonablative treatment relies on epidermal cooling to deliver adequate energy to the dermis. The spared zone is marginal and significantly smaller than the zone of thermal damage. Bulk heating interferes with the release of key signaling mediators resulting in an inadequate regenerative signal. Complete sparing of the epidermis via cooling also blocks epidermal turnover leading to an absence of “resurfacing.”

cascade that leads to increased expression of heat shock protein 70, among others.¹⁴ This appears to, in turn, cause up-regulation of transforming growth factor β , which facilitates dermal remodeling by increasing collagen synthesis.^{6,14} At 72 hours after treatment, the epidermis has already reepithelialized with partial restoration of the basement membrane (Figure 3B).¹⁴ By 7 days after treatment, most of the MEND have been exfoliated whereas complete replacement of MTZs with new collagen occurs by 3 months. Table 2 summarizes the wound healing process between 0 and 3 months after FP treatment.

Clinical Efficacy of Fractional Photothermolysis

Already, numerous reports regarding FP have indicated successful treatment of a wide variety of dermatologic conditions including melasma, poikiloderma, acne scars, and rhytides.^{6,11,15-17} As mentioned above, clinicians have long struggled to effectively treat melasma, especially when dermal in location. In the first known clinical study of melasma using FP, Tannous and Astner¹³ found that a Caucasian female with Fitzpatrick skin type II to III showed marked improvement after two treatment sessions 3 weeks apart. The only adverse effects

TABLE 2. Chronology of Wound Healing after Fractional Photothermolysis Treatment*

<i>Timeline after treatment</i>	<i>Effects</i>
Immediately	Complete loss of dermal reflection under in vivo confocal microscopy
1 hour	MTZs fully developed with loss of birefringence; surge in HSP 70 expression triggered
1 day	Formation of MEND; basal epidermal stem cells continue reepithelialization process
3 days	MEND found between the epidermis and stratum corneum; reepithelialization complete
5 days	MEND entirely within stratum corneum; TGF- β up-regulation
1 week	Significant MEND exfoliation; collagen type 3 synthesis begins
1 month	MEND exfoliation complete; collagen type 3 replaced by type 1
3 months	Complete replacement of MTZs by neocollagenesis

*Data from Reference 12.

HSP, heat shock protein; MEND, microepidermal necrotic debris; MTZ, microscopic treatment zone; TGF, transforming growth factor.

reported were erythema and bronzing of the skin, both resolving in 2 to 3 days after treatment. In an additional pilot study initiated by Rokhsar and Fitzpatrick,⁸ 6 of 10 melasma patients with Fitzpatrick skin types III to IV showed 75% to 100% symptom reduction after four to six treatment sessions in 1- to 2-week intervals.⁸ Posttreatment side effects included 2 to 3 days of residual erythema and facial edema. Hyperpigmentation persisting through the 3-month study period was observed in one Hispanic patient with Fitzpatrick skin type V, although four others with identical ethnic background and skin type reported no problems. The authors also reported a rare occurrence of 2 to 3- \times 8 to 16-mm small linear abrasions when using higher density settings (3,500 MTZ/cm²). These appeared 3 to 5 days after treatment but resolved without complication within 1 to 2 days in all cases. At 2,000 to 3,500 MTZ/cm² and pulse energy levels of 6 to 12 mJ, a mean pain score of 6.3 on a scale of 1 to 10 was reported in this cohort. The mechanism underlying the efficacy of FP for treatment of melasma was recently elucidated by Hantash and coworkers⁹ and is discussed in detail above (see "Biology of Fractional Photothermolysis").

Photodamage is a well-documented dermatologic condition that is characterized by development of dyschromia, telangiectasia, rhytides, and textural changes. Elastin and collagen fiber fragmentation in the papillary dermis is noted histologically, and topical creams such as retinoids have proven mar-

ginally effective.^{18,19} Thus far, use of nonablative infrared lasers for the treatment of photoaging has not resulted in dramatic or reliable improvements.⁵ This is primarily attributed to the therapeutic index of SP devices, with increased energy levels required for adequate clinical outcomes. Adverse events, however, also increase and thus have led to narrow treatment windows and use of cooling devices. Treatment with FP has overcome this challenge by generating very high pulse energy treatments in microscopic zones of skin and thus avoided limitations of bulk heating.⁶ This principle therefore relies on the extensive volume of untreated tissue (normally damaged by nonfractional treatment) to participate in the wound healing response. Behroozan and colleagues¹¹ recently reported successful treatment of poikiloderma around the neck of a patient with Fitzpatrick skin type II. In this study, complete resolution was observed within 2 weeks after only one treatment session (2,000 MTZ/cm² at 8 mJ) with no recurrence noted at the 2-month follow-up. The only posttreatment side effect noted was edema, which subsided by the day's end.

Manstein and coworkers⁶ studied the efficacy of FP for treatment of periorbital rhytides in 30 subjects with Fitzpatrick skin type II to III. In this study, patients underwent four treatments (2,500 MTZ/cm² at 6–12 mJ) over a 2- to 3-week period. In 10% of patients, erythema and edema persisted for up to 1 week, a not surprising outcome considering the decreased time interval between successive treatments.

Notwithstanding, overall treatment was still well tolerated by patients with a mean pain score of 3.2 on a scale of 1 to 10. By 1 month after treatment, wrinkle appearance and texture quality were moderately (score of 4 on a scale of 1–6) improved in 54 and 53% of subjects, respectively, as assessed by independent investigators. This benefit persisted at the 3-month follow-up, with 34 and 47% of subjects, respectively, rated as moderately improved. In this study, subjective and objective scores were not found to be significantly different at either the 1- or the 3-month time point. Overall, 96% of patients experienced mild to moderate improvement in wrinkles and skin texture.

FP has also proven equally efficacious for scar treatment.^{20–23} In a pilot study conducted by Glaich and colleagues,²⁰ seven Fitzpatrick skin types I to IV subjects with hypopigmented scarring due to acne (6) and burn (1) reported subjective improvement after FP treatment. Each subject underwent two to four treatments (1,000–2,500 MTZ/cm² at pulse energies of 7–20 mJ) at 4-week intervals with a mean improvement of 51% to 75% based on independent physician assessment. Side effects were limited to posttreatment erythema and edema, both resolving within 2 to 4 days. Behroozan and coworkers²¹ reported similar results for a patient with hypertrophic scar of the chin after a single treatment (2,000 MTZ/cm² at pulse energy of 8 mJ). These findings were recently confirmed by Alster and coworkers²³ who investigated the efficacy of FP treatment for facial atrophic acne scars in 53 patients, the largest prospective trial to date. Patients were treated with 8 to 10 passes at 125 to 250 MTZ/cm² and fluence of 8 to 16 J/cm² delivering a total energy of 4 to 6 kJ per session. In this study, masked assessors reported a 25% to 50% clinical improvement in 91% of patients after a single treatment. Mean clinical scores increased incrementally after each treatment with a 51% to 75% improvement noted in 87% of patients that received three treatments at 4-week intervals. Interestingly, this benefit was maintained over time, as the investigators found no significant difference in clinical scores at the 6-month follow-up. The authors

also concluded that FP treatment showed a similar mild and limited side effect profile across all Fitzpatrick skin types. These findings lend further support for a renewed excitement amongst physicians who treat patients with darker skin types, where lasers have been of limited utility due to the higher risk of pigmentary alteration.

FP's long-term efficacy in treating facial and nonfacial photodamage, rhytides, and dyspigmentation was recently elucidated in a clinical study conducted by Wanner and coworkers.²⁴ Fifty patients with Fitzpatrick skin types I to III underwent a series of three consecutive treatments (2,000 MTZ/cm² at 8 mJ for facial areas; 1,500–2,000 MTZ/cm² at 8 mJ for nonfacial areas) spaced 3 to 4 weeks apart. Clinical improvement was objectively assessed by two blinded independent physicians using a quartile grading scale (0 = <25%; 1 = 25%–50%; 2 = 51%–75%; 3 = >75%). The investigators reported a mean improvement of 2.23, 2.10, and 1.96 at 3, 6, and 9 months after treatment, respectively. Similar results were observed for nonfacial areas, with a mean improvement of 1.85, 1.81, and 1.70 at 3, 6, and 9 months after treatment, respectively. An overall improvement of 51% to 75% was found in 73% (facial arm) and 55% (nonfacial arm) of patients 9 months after treatment. In this cohort, adverse effects were limited and short-lived. All patients experienced erythema with a mean duration of 2.9 days, 68% of who also reported edema lasting a mean of 1.6 days.

Fisher and Geronemus²⁵ recently investigated the frequency of 14 different short-term adverse effects by surveying subjects immediately post-FP treatment over consecutive sessions. In this study, all surveyed subjects reported resolution of erythema within 3 days. Xerosis was initially observed 2 days after treatment and resolved after topical moisturization 3 to 4 days later. Localized edema was noted in 82% of cases and varied widely among subjects. Other side effects such as pruritis and scarring were reported and are summarized in Table 1.⁷ Nearly 75% of patients were able to fully resume

social activities within 2 days, consistent with a minimal downtime treatment.²⁵ In this series, the mean pain score reported by patients was 4.6 on a 10 scale after treatment with 2,000 MTZ/cm² at pulse energies of 8 to 12 mJ. These data are in agreement with those reported by Wanner and coworkers²⁴ although the latter authors did also observe two cases of acneiform eruption, both of which resolved in 2 weeks without any further treatment (see Table 1).

Rarely, systemic toxicity due to increased lidocaine skin penetration can occur after FP treatment.²⁶ Of the approximately 1,000 patients treated with FP in the office of Moy and colleagues,²⁶ only two cases were observed both following large surface area (entire back for one, face and neck in a second) topical anesthesia with lidocaine 30% gel for 60 minutes. In both cases, the lidocaine gel was not removed before laser treatment. Within 5 minutes after treatment, the reported patient became agitated and light-headed and complained of palpitations, nausea, and perioral tingling—all early signs of systemic lidocaine toxicity. The authors hypothesized that FP treatment altered skin barrier function leading to increased percutaneous absorption of lidocaine. The period of time that elapsed during FP treatment was not discussed. Because most early adopters treated through the anesthetic layer without reports of lidocaine toxicity, an idiosyncratic reaction due to the patient's metabolic profile represents an equally plausible explanation. Moreover, the presenting signs and symptoms of the patient combined with the measured nontoxic plasma lidocaine level of 1.5 µg/mL are more suggestive of an acute panic attack. Indeed, both alternatives were considered by the authors who correctly cited the patient's low body mass index and history of anxiety attacks as other possible predisposing factors. Although it remains unclear whether skin barrier alteration as a result of FP treatment played a role in the above case, removal of topical anesthesia before laser treatment is currently recommended and would help obviate future risk of anesthetic toxicity. Overall, it appears that side effects are transient and resolve

within a few days for most patients. This provides the physician with a therapeutic treatment modality for a wide array of clinical indications while preserving a minimal downtime side effect profile required by patients.

Conclusion

FP is a novel mechanism recently developed as an alternative to both ablative and nonablative devices that utilize the principle of SP. Through the use of a specialized optical tracking system, the 1,550-nm erbium-doped fiber laser is capable of creating a microarray pattern of thermal coagulation zones that allows physicians to avoid bulk heating of target tissue. This unique system utilizes a scanning hand-piece capable of continuous treatment up to 8 cm/second, providing a distinct speed advantage over characteristic stamping lasers. The FP approach has already proven efficacious for conditions such as melasma, fine wrinkles, poikiloderma, and scars. Although this revolutionary technology remains in its infancy, future studies will undoubtedly continue to unravel its biologic mechanisms, thereby broadening the range of therapeutic options for otherwise difficult-to-treat dermatologic conditions.

References

1. Weiss RA, Weiss MA, Beasley KL, Munavalli G. Our approach to non-ablative treatment of photoaging. *Lasers Surg Med* 2005;37:2–8.
2. Anderson RR, Parrish JA. Selective photothermolysis: precise microsurgery by selective absorption of pulsed radiation. *Science* 1983;220:524–7.
3. Tunnell JW, Chang DW, Johnston C, et al. Effects of cryogen spray cooling and high radiant exposures on selective vascular injury during laser irradiation of human skin. *Arch Dermatol* 2003;139:787–8.
4. Ross EV, Yashar SS, Naseef GS, et al. A pilot study of in vivo immediate tissue contraction with CO₂ skin laser resurfacing in a live farm pig. *Dermatol Surg* 1999;25:851–6.
5. Shook BA, Hruza GJ. Periorbital ablative and non-ablative resurfacing. *Facial Plast Surg Clin N Am* 2005;13:571–82.
6. Manstein D, Herron GC, Sink RK, et al. Fractional photothermolysis: a new concept for cutaneous remodeling using microscopic patterns of thermal injury. *Lasers Surg Med* 2004;34:426–38.

7. Geronemus RG. Fractional photothermolysis: current and future applications. *Lasers Surg Med* 2006;38:169–76.
8. Rokhsar CK, Fitzpatrick RE. The treatment of melasma with fractional photothermolysis: a pilot study. *Dermatol Surg* 2005;31:1645–50.
9. Hantash BM, Bedi VP, Sudireddy V, et al. Laser-induced trans-epidermal elimination of dermal content by fractional photothermolysis. *J Biomed Opt* 2006;11:041115.
10. Khan MH, Sink RK, Manstein D, et al. Intradermally focused infrared laser pulses: thermal effects at defined tissue depths. *Lasers Surg Med* 2005;36:270–80.
11. Behroozan DS, Goldberg LH, Glaich AS, et al. Fractional photothermolysis for treatment of poikiloderma of Civatte. *Dermatol Surg* 2006;32:298–301.
12. Fisher GH, Kim KH, Bernstein LJ, Geronemus RG. Concurrent use of a handheld forced cold air device minimizes patient discomfort during fractional photothermolysis. *Dermatol Surg* 2005;31:1242–4.
13. Tannous ZS, Astner S. Utilizing fractional resurfacing in the treatment of therapy-resistant melasma. *J Cosmet Laser Ther* 2005;7:39–43.
14. Laubach HJ, Tannous Z, Anderson RR, Manstein D. Skin responses to fractional photothermolysis. *Lasers Surg Med* 2006;38:142–9.
15. Chan HH. Effective and safe use of lasers, light sources, and radiofrequency devices in the clinical management of Asian patients with selected dermatoses. *Lasers Surg Med* 2005;37:179–85.
16. Tse Y. Treatment of melasma using a novel 1550 nm (Fraxel) laser. *Lasers Surg Med* 2005;S17:100.
17. Kim KH, Fisher GH, Bernstein LJ, et al. Treatment of acneiform scars with fractional photothermolysis. *Lasers Surg Med* 2005;S17:93.
18. Airan LE, Hruza GJ. Current lasers in skin resurfacing. *Facial Plast Surg Clin North Am* 2002;10:87–101.
19. Sefton J, Kligman AM, Kopper SC, et al. Photodamage pilot study. a double-blind, vehicle-controlled study to assess the efficacy and safety of tazarotene 0.1% gel. *J Am Acad Dermatol* 2000;43:656–63.
20. Glaich AS, Rahman Z, Goldberg LH, Friedman PM. Fractional resurfacing for the treatment of hypopigmented scars: a pilot study. *Dermatol Surg* 2006;32:in press.
21. Behroozan DS, Goldberg LH, Dai T, et al. Fractional photothermolysis for the treatment of surgical scars: a case report. *J Cosmet Laser Ther* 2006;8:35–8.
22. Hasegawa T, Matsukura T, Mizuno Y, et al. Clinical trial of a laser device called fractional photothermolysis system for acne scars. *J Dermatol* 2006;33:623–7.
23. Alster TS, Tanzi EL, Lazarus M. The use of fractional photothermolysis for the treatment of atrophic scars. *Dermatol Surg* 2007;33:in press.
24. Wanner M, Tanzi EL, Alster TS. Fractional photothermolysis: treatment of facial and non-facial cutaneous photodamage with a 1550 nm erbium-doped fiber laser. *Dermatol Surg* 2007;33:23–8.
25. Fisher GH, Geronemus RG. Short term side effects of fractional photothermolysis. *Dermatol Surg* 2005;31:1245–9.
26. Marra DE, Yip D, Fincher EF, Moy RL. Systemic toxicity from topically applied lidocaine in conjunction with fractional photothermolysis. *Arch Dermatol* 2006;142:1024–6.
27. Ostertag JU, Quaedvlieg PJ, Neumann MH, Krekels GA. Recurrence rates and long-term follow-up after laser resurfacing as a treatment for widespread actinic keratoses on the face and scalp. *Dermatol Surg* 2006;32:261–7.
28. Sriprachya-anunt S, Marchell NL, Fitzpatrick RE, et al. Facial resurfacing in patients with Fitzpatrick skin type IV. *Lasers Surg Med* 2002;30:86–92.
29. Tanzi EL, Alster TS. Single-pass carbon dioxide versus multiple-pass Er:YAG laser skin resurfacing: a comparison of postoperative wound healing and side-effect rates. *Dermatol Surg* 2003;29:80–4.
30. Alster TS, Doshi SN, Hopping SB. Combination surgical lifting with ablative laser skin resurfacing of facial skin: a retrospective analysis. *Dermatol Surg* 2004;30:1191–5.
31. Schwartz RJ, Burns AJ, Rohrich RJ, et al. Long-term assessment of CO₂ facial laser resurfacing: aesthetic results and complications. *Plast Reconstr Surg* 1999;103:592–601.
32. Chua SH, Ang P, Khoo LS, Goh CL. Nonablative 1450-nm diode laser in the treatment of facial atrophic acne scars in type IV to V Asian skin: a prospective clinical study. *Dermatol Surg* 2004;30:1287–91.
33. Levy JL, Trelles M, Lagarde JM, et al. Treatment of wrinkles with nonablative 1,320-nm Nd:AG laser. *Ann Plast Surg* 2001;47:482–8.

Address correspondence and reprint requests to:
 Basil M. Hantash, MD, PhD, Department of Dermatology
 and Division of Plastic Surgery, Stanford University School
 of Medicine, 257 Campus Drive, Stanford, CA 94305-
 5148, or e-mail: bhantash@stanford.edu.