

# Repair of Nasal Tip and Alar Defects Using Cheek-Based 2-Stage Flaps



## *An Alternative to the Median Forehead Flap*

Harvey Smith, MBBS, MRCP; Timothy Elliott, MBBS, FACD; Carl Vinciullo, MBBS, FACD

**Objective:** To describe our use of cheek-based 2-stage transposition flaps for repairing Mohs surgery defects of the lower third of the nose.

**Design:** Retrospective case series.

**Setting:** Private dermatologic day surgery facility.

**Patients:** Twenty-eight patients with defects of the lower third of the nose after Mohs surgery.

**Intervention:** Ten alar and 18 nasal tip defects repaired using cheek-based 2-stage transposition flaps.

**Main Outcome Measures:** Acceptability of procedure to patient, complications, and appearance from photographic records.

**Results:** The procedures were well tolerated and achieved good cosmetic results without major complications.

**Conclusions:** These flaps allow repair of extensive defects of the nasal tip and ala with the patient under local anesthesia. This approach provides an alternative to the median forehead flap for nasal tip repairs.

*Arch Dermatol.* 2003;139:1033-1036

**R**ECONSTRUCTION OF the nose after Mohs surgery can be challenging. The lower third of the nose is composed of the nasal tip and alar lobules, which are composite structures: a framework of cartilage suspends a sheet of fibrofatty tissue and skin. The alar rim is a free, unsupported margin that is easily distorted by scar contracture. In these areas, the skin is sebaceous, unlike the skin of the nasal dorsum and sidewalls.

After Mohs surgery, the cosmetic units need to be restored, with skin color and texture maintained. Structural support for the alar rim may be needed to prevent notching due to scar contracture and alar collapse on inspiration (nasal valve effect). Options for repair include healing by second intention, full-thickness skin graft, primary closure, or flaps. Transposition flaps use reserves of tissue from the forehead, cheek, or nose and are carried out in 1 or 2 stages. Two-stage procedures use a temporary bridging pedicle to nourish the transposed tissue while a local blood supply is established.

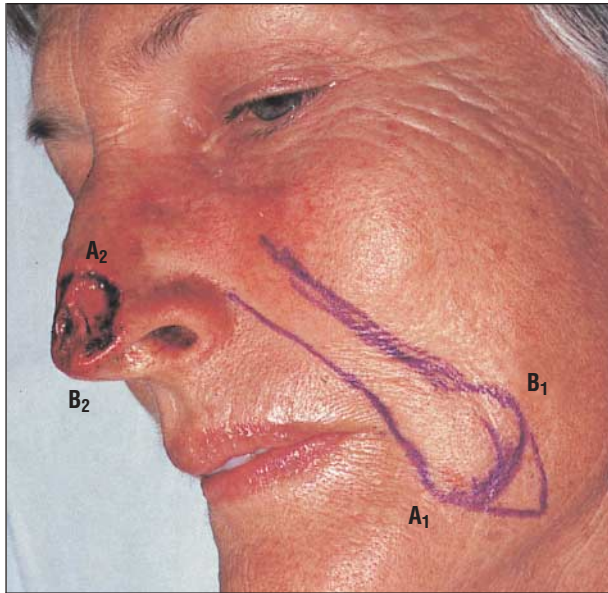
We describe our experience using cheek-based 2-stage transposition flaps for repair of the nasal tip and ala: the superiorly based nasolabial flap<sup>1</sup> (Burge flap) and the cheek-to-nose or nasofacial interpola-

tion flap (interpolation flap).<sup>2,3</sup> These flaps transpose matching skin from just lateral to the nasolabial fold. Both flaps have a rich random-pattern blood supply that is derived from subcutaneous branches of the facial and angular arteries that perforate the levator labii muscle near the ala. The 2 flaps differ principally in pedicle length; central defects can be repaired by the longer reach of the interpolation flap. Another difference is found in the supporting pedicle. The Burget flap is tapered proximally with a muscular element to the pedicle, which ensures an adequate blood supply during the significant rotation required to repair alar defects. The interpolation flap has a wide base, without a muscular element, to maintain blood supply over its significant length.

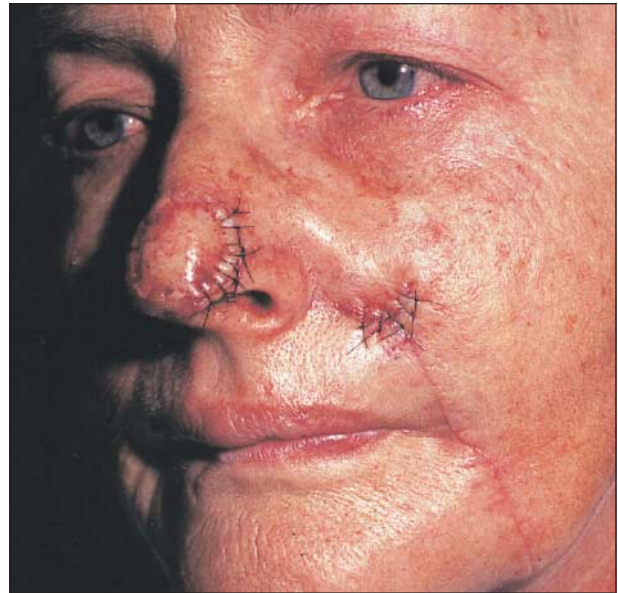## METHODS

Over a 4-year period, all patients who had Mohs surgery defects repaired using the Burget or interpolation flap were identified. Defects were assessed from the notes by size, site, involvement of cartilage, and internal nasal lining. The repair used and any complications during the postoperative period were also recorded. The operative technique used to close the defect, complications, and need for revision at review were assessed. All repairs were performed with the patients under local anesthesia.

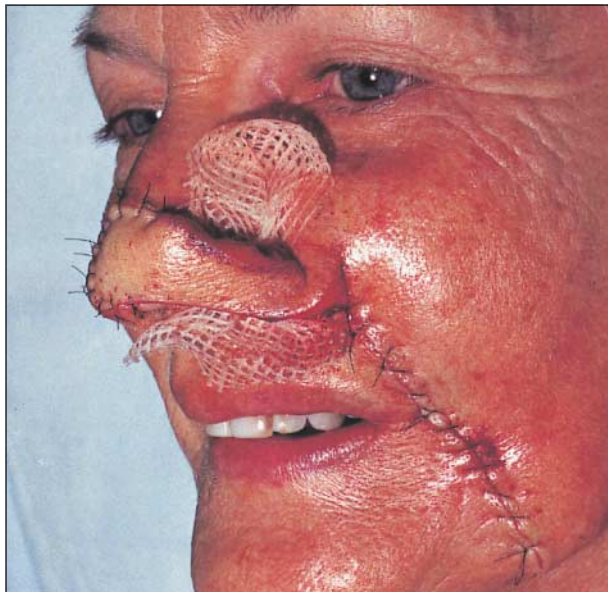*From the Dermatology, Surgery, and Laser Center, Perth Surgicenter, South Perth, Australia. Dr Smith is now with the Department of Dermatology, Royal Hospital Haslar, Hampshire, England. The authors have no financial interest in this article.*



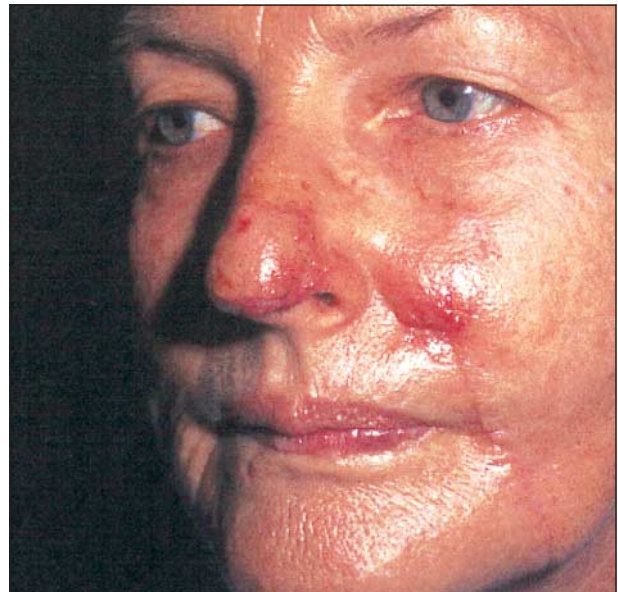**Figure 1.** Subject with a Mohs nasal tip defect  $A_2$ — $B_2$ . Interpolation flap template marked to include donor skin  $A_1$ — $B_1$ .



**Figure 3.** At 3 weeks, the proximal pedicle is amputated close to the skin and the donor skin is defatted and inset.



**Figure 2.**  $A_1$  has moved to  $A_2$  and  $B_1$  to  $B_2$ . Paraffin impregnated gauze has been wrapped around the pedicle. The secondary defect is tapered to lie in the nasolabial crease.

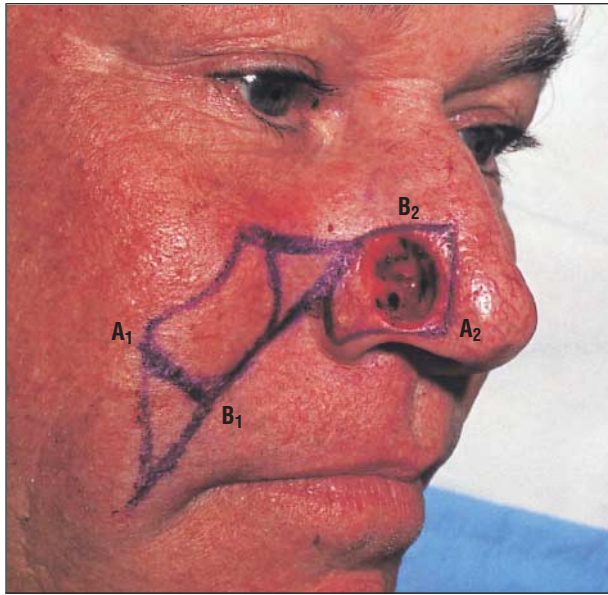


**Figure 4.** The patient 1 month after initial surgery.

The interpolation flap was used for repairing defects involving the nasal tip. The defects were extended if necessary to fit the nasal tip cosmetic unit. **Figure 1** shows a subject with a significant nasal tip defect. A template for an interpolation flap has been designed running along the nasolabial crease so that the donor skin ( $A_1$ — $B_1$ ) will reach the defect ( $A_2$ — $B_2$ ) without tension. The result of moving  $A_1$  to  $A_2$  and  $B_1$  to  $B_2$  is seen in **Figure 2**. The base of the flap must be wide enough to support the random-pattern blood supply of the pedicle. The distal end of the flap ( $A_1$ — $B_1$ ) is thinned depending on the depth of the defect and sutured into place. Paraffin-impregnated gauze is wrapped around the pedicle, and the secondary defect is tapered distally so that the scar lies in the nasolabial crease. **Figure 3** shows the subject after the second stage at 3 weeks. This delay ensures firm attachment and revascularization of the donor skin. The pedicle is divided, and the distal end is defat-

ted and inset into the defect. The proximal pedicle is amputated close to the skin, defatted, and inset with a "V" configuration. **Figure 4** shows the patient 1 month after initial surgery.

Isolated alar defects were repaired using the Burget flap. In **Figure 5**, the post-Mohs defect was enlarged as marked to include the entire alar cosmetic unit. A template fashioned from the contralateral intact ala is inverted and laid adjacent to the nasolabial crease. This inversion ensures that on inferior rotation of the flap as seen in **Figure 6**,  $B_1$  is brought to  $B_2$  and  $A_1$  to  $A_2$ . The arrow in **Figure 7** indicates the myocutaneous pedicle that bridges to the center of the flap. The pedicle is dissected and mobilized to provide up to 150° of inferior rotation for the flap. The secondary defect is then closed, ensuring that the scar lies in the nasolabial line. At 3 weeks, the flap is divided. The contour of the ala is re-created by excising the remnant alar sill and inserting the new donor skin. **Figure 8** shows the clinical result in the patient 3 years after the initial procedure.

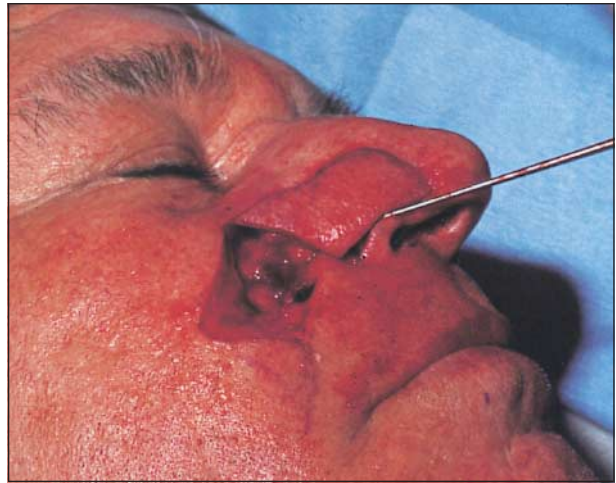

**Figure 5.** Subject with a post-Mohs alar defect A<sub>2</sub>—B<sub>2</sub>. A template for a Burget flap is marked including donor skin A<sub>1</sub>—B<sub>1</sub>.

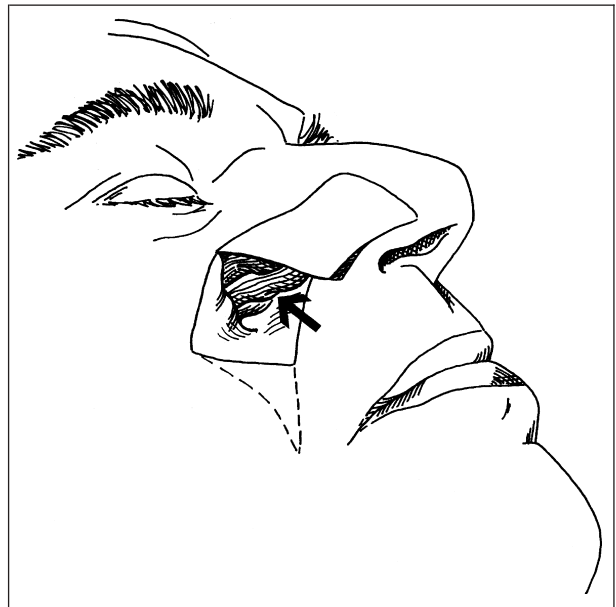## RESULTS

Twenty-eight patients (15 men and 13 women; age range, 43-69 years; average age, 67 years) underwent 2-stage repairs of Mohs defects of the nasal tip and ala between 1997 and 2001. At preoperative assessment, surgery in all patients seemed likely to risk breaching the nasal mucosa. Therefore, in keeping with recent recommendations, they received antibiotic prophylaxis on the day of surgery with 1 g of cephalexin at the time of surgery, followed by 500 mg 6 hours later.<sup>†</sup> Twenty-four patients underwent surgery for primary lesions, and 4 patients underwent surgery for recurrences. Twenty-seven lesions were basal cell carcinomas: 14 were infiltrating, 2 basosquamous, and the rest nodular. One was a well-differentiated squamous cell carcinoma. Defect size varied from 1.2 × 1.0 cm to 3.0 × 2.5 cm (mean defect size, 2.2-1.8 cm). The defect was restricted to the ala in 10 cases, and all 10 defects were repaired with the Burget flap. In 18 cases, the defects predominantly involved the nasal tip and were repaired with an interpolation flap. A conchal cartilage graft was required to provide structural cartilage support in 17 cases. Mucosal defects occurred in 6 cases. In 5 of the 6 cases, internal nasal lining was provided as part of a conchal cartilage composite graft, with the conchal skin forming the nasal lining; in 1 case, the mucosal defect closure was direct.

In 4 cases (2 of each repair), a clinical diagnosis of wound infection was made in the first week. Wound swabs were sent for culture and yielded *Staphylococcus aureus* in 2 cases. In a fifth case, *Pseudomonas* was cultured from an infected conchal cartilage donor site. These cases all responded to oral antibiotic therapy. In 6 interpolation flaps, minor bleeding or duskiness occurred during the first week. On review of the 6 repairs, no adverse effects were observed. Three patients with interpolation flaps developed hair growth from the donated skin sufficient to require specific treatment with a hair-specific laser (PhotoGenica LPIR; Cynosure Inc, Chelmsford, Mass).



**Figure 6.** The Burget flap has been raised and inferiorly rotated so that B<sub>1</sub> is brought to B<sub>2</sub> and A<sub>1</sub> to A<sub>2</sub>.



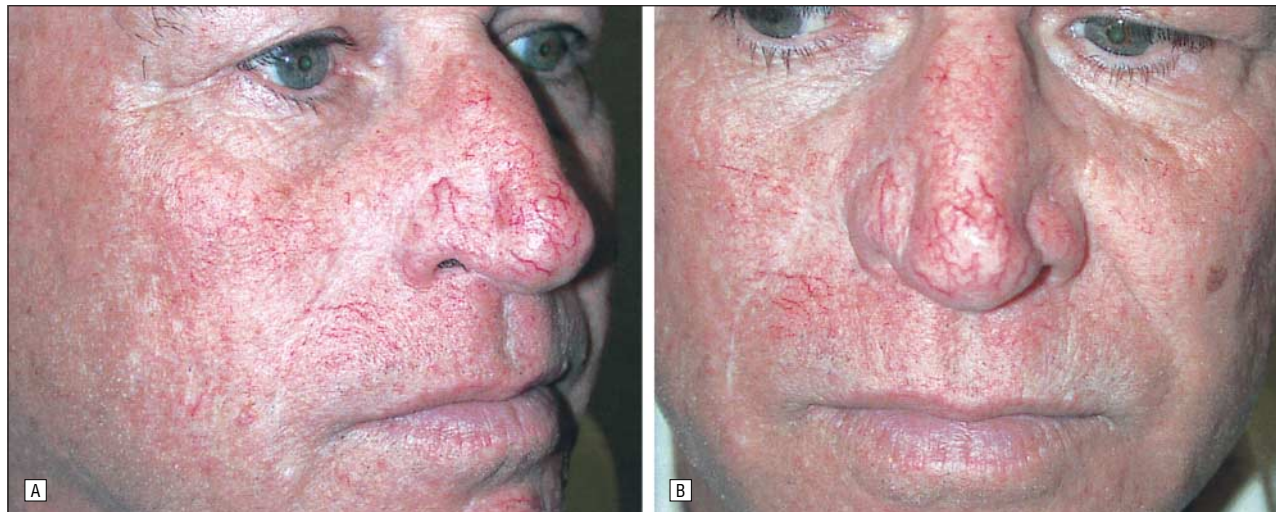**Figure 7.** The arrow indicates the myocutaneous pedicle that has been raised and dissected to allow inferior rotation.

One patient with a Burget flap developed a significant complication, becoming erythematous and swollen in the first week. Oral antibiotic therapy was initiated. Superficial tip necrosis developed, and division was delayed for 6 weeks. Despite this setback, the result at 1 year was satisfactory. The complication occurred in a patient who smoked approximately 50 cigarettes a day.

All cases were reviewed after a period ranging from 6 months to 3 years. None of the repairs required a secondary procedure. Furthermore, no tumor recurrences have occurred to date.

## COMMENT

The Burget and interpolation flaps are described in the literature for repair of the nasal ala.<sup>1-3</sup> Both flaps could be extended to reach the nasal tip. Herein, we describe lengthening of the interpolation flap. In our opinion, of the 2 flaps, the interpolation flap is technically easier to extend. The



**Figure 8.** The clinical result 3 years after the initial procedure.

interpolation flap, vascularized by a subdermal plexus, can achieve considerable length without restriction of movement. The muscular pedicle of the Burget flap provides an excellent blood supply but is more restrictive to movement. The dissection and mobilization of this pedicle to allow the lengthened flap to reach the nasal tip represent a greater surgical challenge.

There were few satisfactory alternatives to the Burget and interpolation flaps in these cases. Second-intention healing would produce a poor cosmetic result: the contour of the tip would be disrupted, and contracture would distort the alar free margin. Full-thickness skin grafts are a better option. The best donor site for this sebaceous area would be nasolabial or conchal bowl skin; however, insufficient skin is available at these sites. An alternative would be the single-stage nasolabial transposition flap, which has been criticized for blunting of the nasofacial junction. Zitelli<sup>5</sup> has published a number of modifications that can improve the cosmetic results. Larger lesions located on the medial alar lobule and the nasal tip are not suitable for this flap. The bilobed flap is frequently used for repairs of the lower third of the nose; however, it is based on reserves of tissue from the nose and is limited to smaller defects.<sup>1</sup>

Two-stage transposition flaps preserve the nasofacial sulcus and alar groove. They are a testing procedure for the patient who requires a pedicle across the central area of the face for 3 to 4 weeks. The flap may require secondary revision for “trapdooring” at its proximal and distal ends. In men with beards, hair may be transferred from the nasolabial fold. The numbers in this study have allowed a meaningful comparison of these 2 types of pedicled flaps. The difficulty of design was regarded as similar by all surgeons. The flaps appeared equally acceptable to the patients, and the rate of complications between the 2 flaps were similar. We should point out, however, 2 factors that are fundamental for the success of these flaps: accuracy in design of the pedicle length and adequacy of the pedicle cheek attachment to ensure sufficient blood supply.

In this series, 5 patients developed wound infections and 1 second stage was delayed because of a poor vascular supply. Despite antibiotic prophylaxis, our infection rate is higher than the 2.3% reported for Mohs surgery.<sup>6</sup> This

higher rate suggests that the extent of surgery involved with these repairs and the delay in final wound closure can predispose patients to infection. However, despite these complications, the procedures were well tolerated and produced an acceptable cosmetic outcome: none of the patients in our series has required further revision.

A recent review of the glabellar forehead flap demonstrated its efficacy for the repair of defects of the nasal tip using only local anesthesia.<sup>7</sup> The mean defect size was larger (2.5 × 3.0 cm) than in our series (2.2 × 1.8 cm). Clearly, the glabellar forehead flap represents the “gold standard” in the repair of extensive and complicated nasal tip defects. However, it is a more extensive procedure and is close to the upper limit of what is possible with the use of local anesthesia.<sup>7</sup> In this article, we describe our use of the interpolation flap to repair defects of the nasal tip and the Burget flap to repair defects of the alar lobule. This approach provides an alternative to the median forehead flap for nasal tip repairs, which could then be reserved for more extensive defects.

Accepted for publication February 17, 2003.

We thank Deborah Marirea, Medical Artist, Royal Perth Hospital, Perth, Australia.

Corresponding author and reprints: Harvey Smith, MBBS, MRCP, Department of Dermatology, Royal Hospital Haslar, Gosport, Hampshire, England.

## REFERENCES

1. Burget GC, Menick FJ. *Aesthetic Reconstruction of the Nose*. St Louis, Mo: Mosby-Year Book Inc; 1994.
2. Fader DJ, Baker SR, Johnson TM. The staged cheek-to-nose interpolation flap for reconstruction of the nasal alar rim/lobule. *J Am Acad Dermatol*. 1997;37:614-619.
3. Barlow RJ, Swanson NA. The nasofacial interpolated flap in reconstruction of the nasal ala. *J Am Acad Dermatol*. 1997;36:965-969.
4. Haas AF, Grekin RC. Antibiotic prophylaxis in dermatologic surgery. *J Am Acad Dermatol*. 1995;32:155-176.
5. Zitelli JA. The nasolabial flap as a single-stage procedure. *Arch Dermatol*. 1990;126:1445-1448.
6. Futoryan T, Grande D. Postoperative wound infection rates in dermatologic surgery. *Dermatol Surg*. 1995;21:509-514.
7. Boyd MB, Baker SR, Fader DJ, et al. The forehead flap for nasal reconstruction. *Arch Dermatol*. 2000;136:1365-1370.